

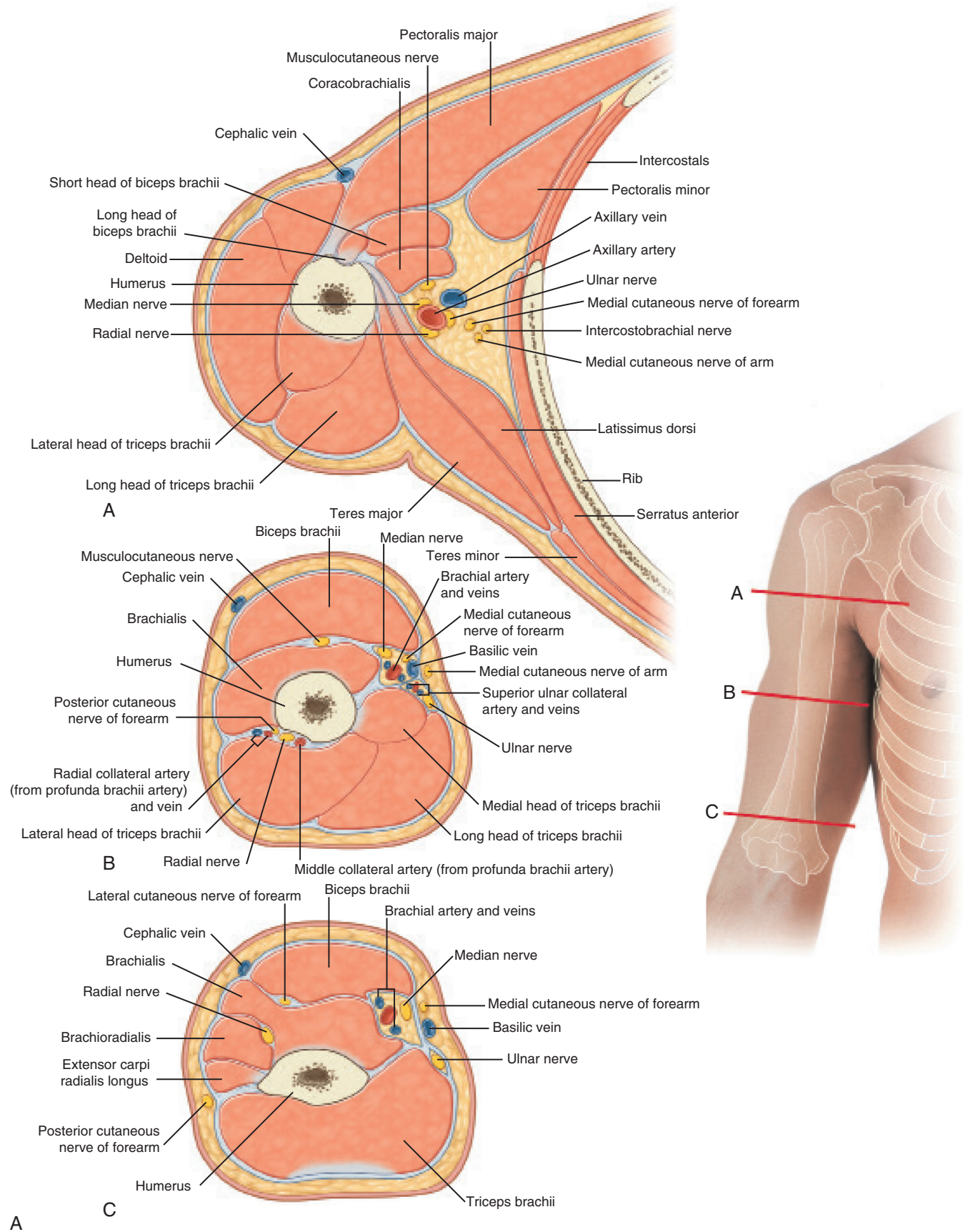FIGURE 2-41 Illustration (A) and imaging (B) of nerves surrounding the humerus. (From Drake RL et al, editors: *Gray's atlas of anatomy*, ed 2, Philadelphia, 2015, Churchill Livingstone.)

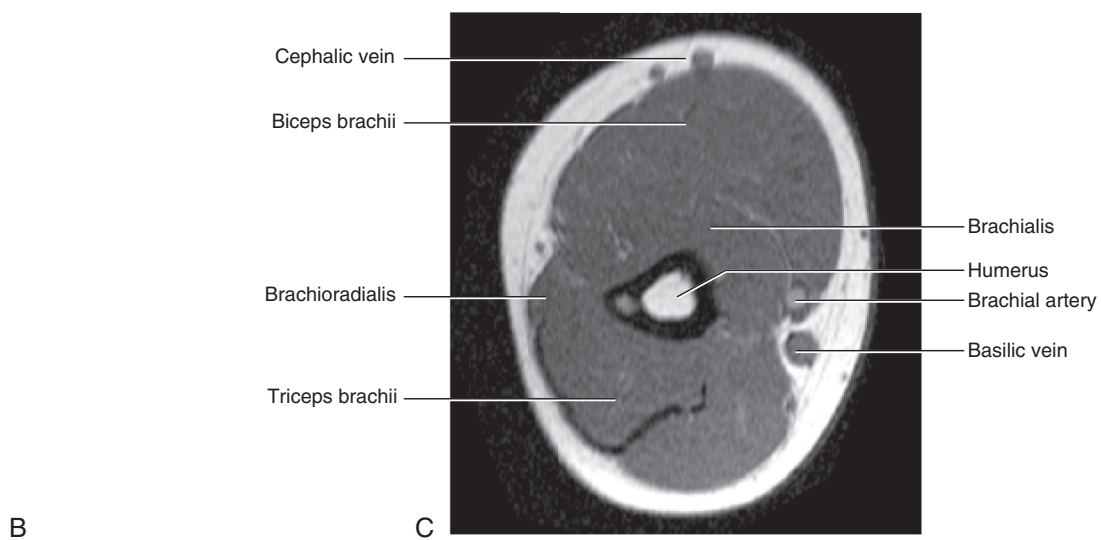
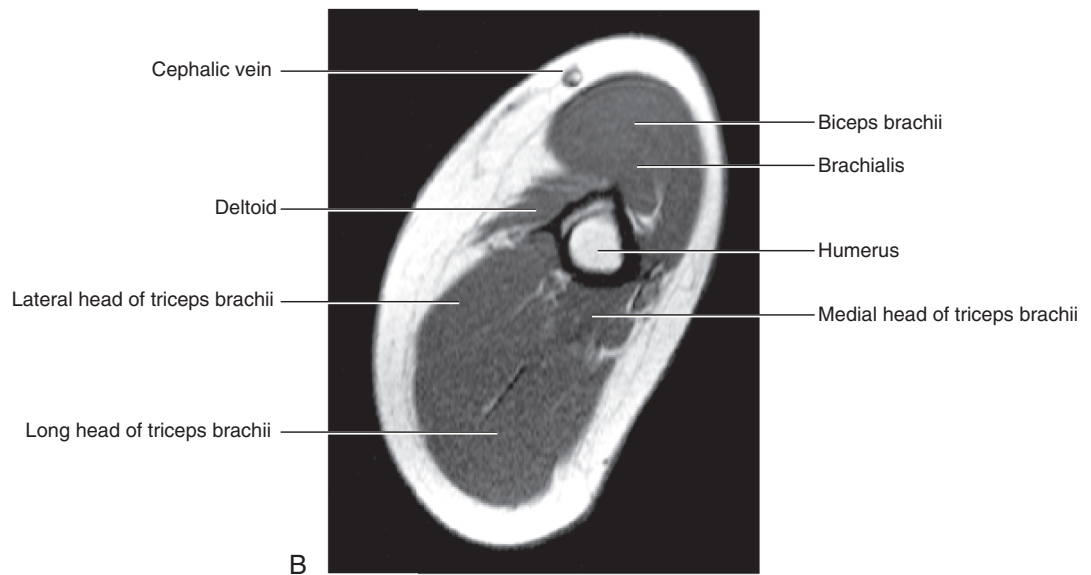
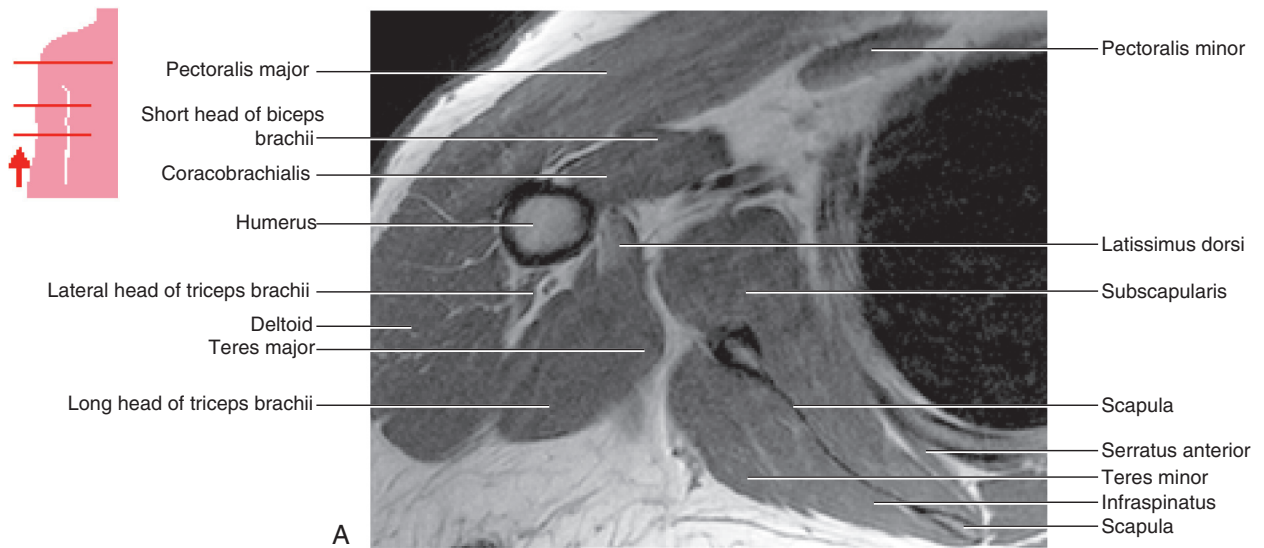


FIGURE 2-41, cont'd

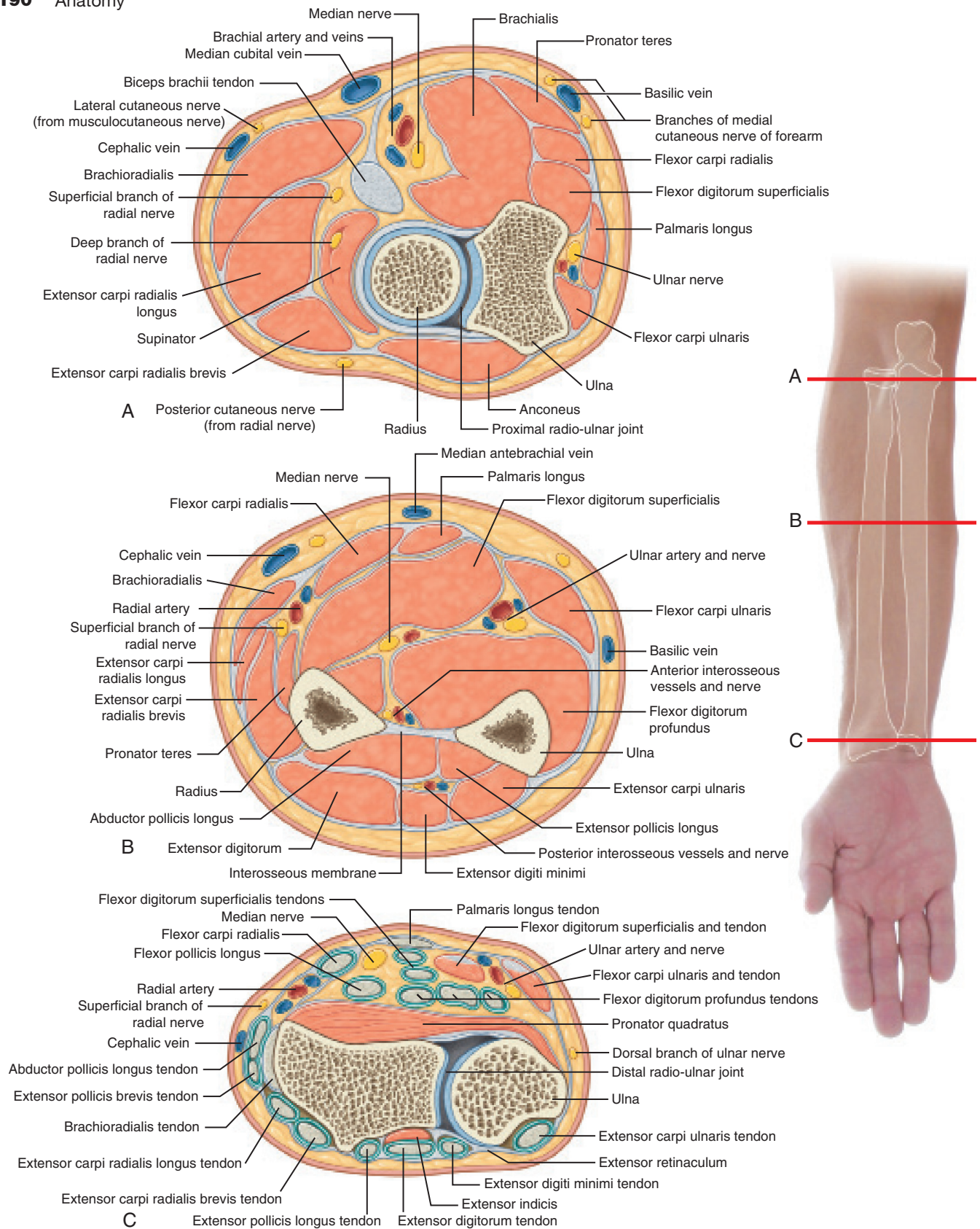
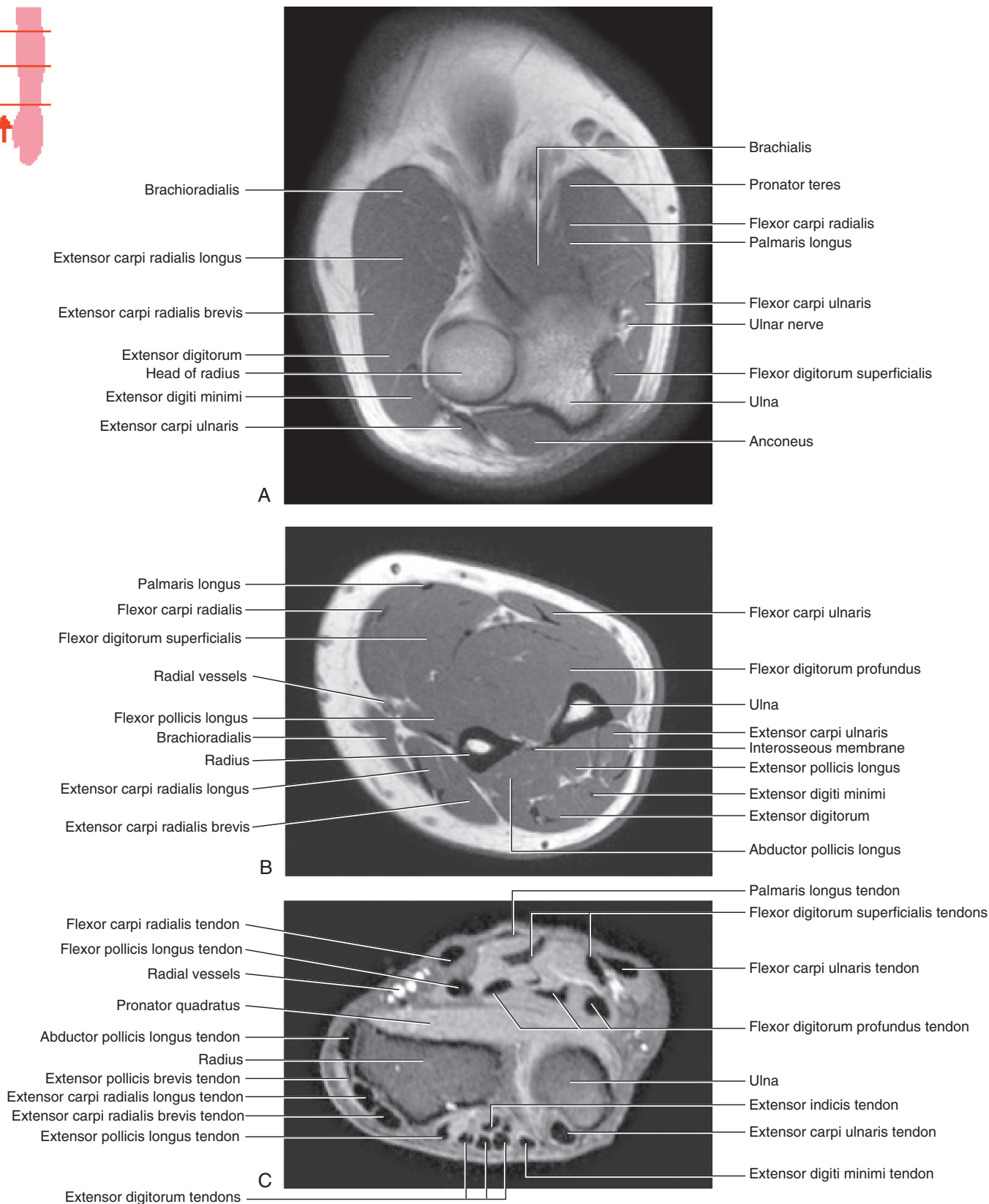


FIGURE 2-42 Illustration (A) and imaging (B) of anatomy of the forearm. (From Drake RL et al, editors: *Gray's atlas of anatomy*, ed 2, Philadelphia, 2015, Churchill Livingstone.)



B

FIGURE 2-42, cont'd

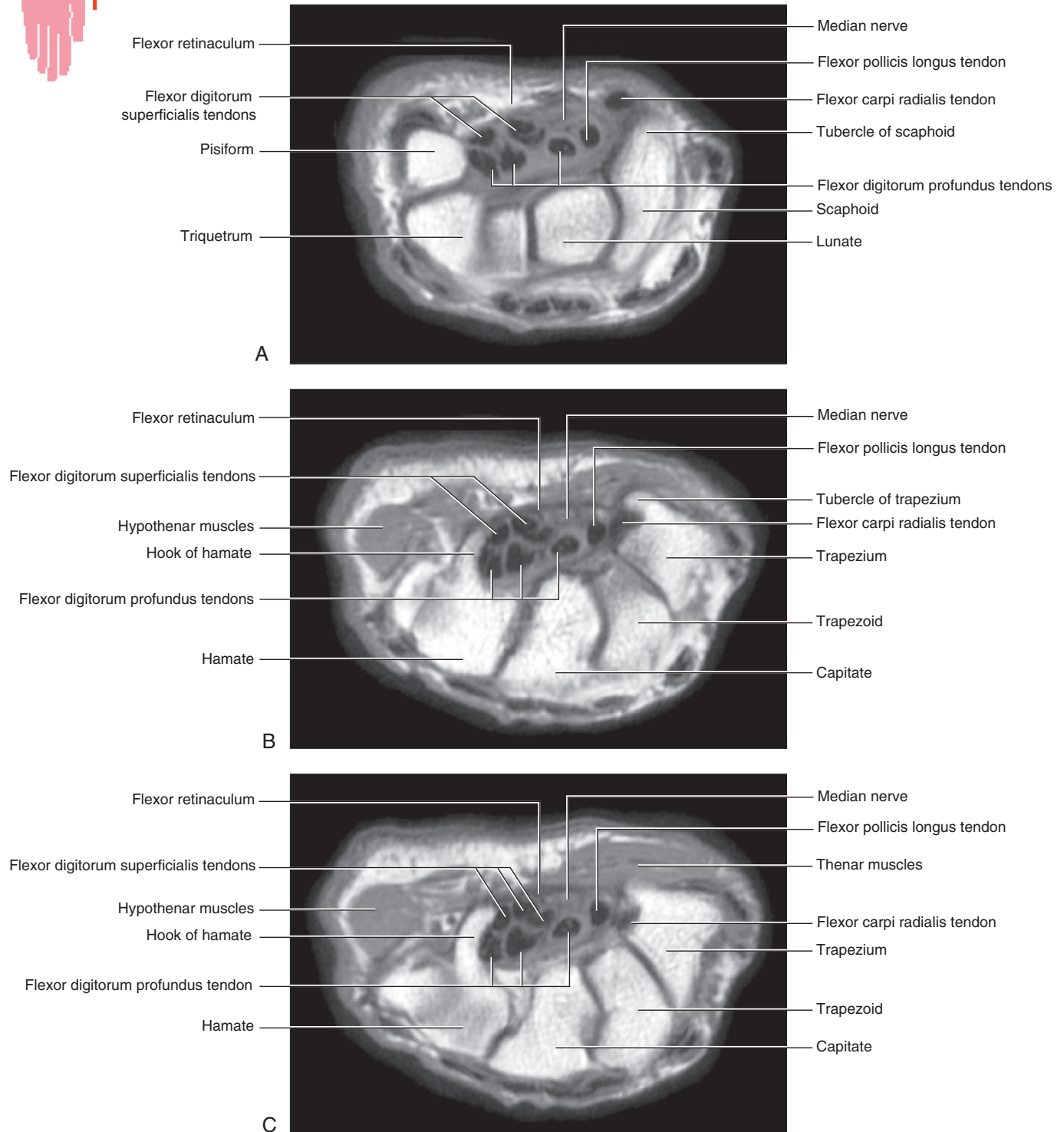


FIGURE 2-43 Imaging of carpal region anatomy. (From Drake RL et al, editors: *Gray's atlas of anatomy*, ed 2, Philadelphia, 2015, Churchill Livingstone.)

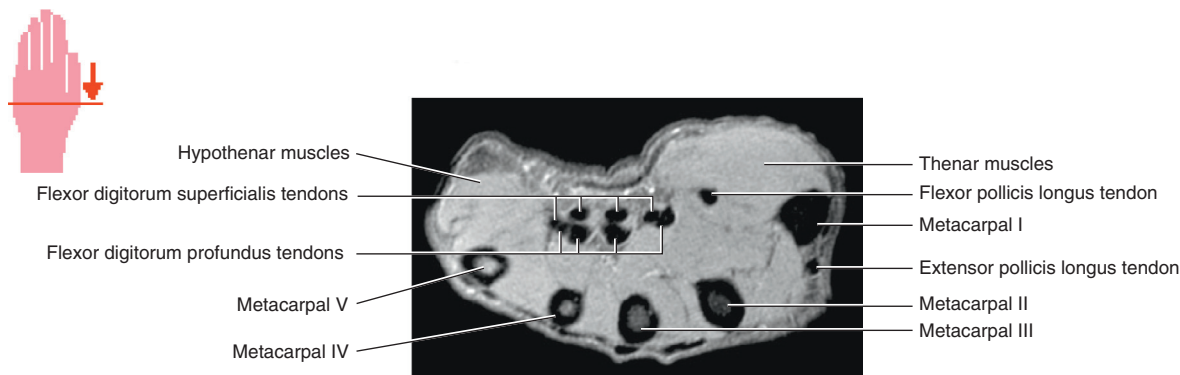


FIGURE 2-44 Imaging of the anatomy of the hand. (From Drake RL et al, editors: *Gray's atlas of anatomy*, ed 2, Philadelphia, 2015, Churchill Livingstone.)

SECTION 3 LOWER EXTREMITY

PELVIS, HIP, AND THIGH

■ Osteology

- Pelvic girdle is composed of two innominate (coxal) bones that articulate with the sacrum and proximal femora.
- Each innominate bone is composed of three united bones: ilium, ischium, and pubis. (Figure 2-45, A and B)
 - Converge in the acetabular fossa at the triradiate fusion center
- Ilium: important landmarks include iliac crest, anterior-superior iliac spine (ASIS), anterior-inferior iliac spine (AIIS), and posterior-superior iliac spine (PSIS)
 - Iliac crest—palpable rim of ilium, important site for bone graft harvest (iliac tubercle 5 cm posterior to ASIS)
 - **ASIS: palpable at lateral edge of inguinal ligament; origin of sartorius muscle and transverse and internal abdominal muscles**
 - **AIIS: less prominent; origin of direct head of the rectus femoris and iliofemoral ligament (Y ligament of Bigelow)**
 - PSIS: 4 to 5 cm lateral to S2 spinous process; important landmark for posterior iliac crest bone graft harvest
- Ischium: posterior column of acetabulum
 - **Iliac spine separates greater and lesser sciatic notch; sacrospinous ligament (anterior sacrum to ischial spine) separates greater and lesser sciatic foramina.**
 - Greater sciatic notch: posterior and superior to acetabulum
 - Ischial tuberosity: origin of hamstrings; sacrotuberous ligament (posterolateral sacrum to ischial tuberosity) inferior border of lesser sciatic foramen
- Pubis: anterior pelvic ring, bilateral pubic rami articulate at pubic symphysis
 - Iliopectineal eminence: anterior pelvic rim prominence at the union of the ilium and pubis
 - Iliopsoas muscle/tendon traverses a groove between iliopectineal eminence and AIIS.
- Acetabulum: normally anteverted (15 degrees) and obliquely oriented in coronal plane (45 degrees caudally)

- Posterosuperior articular surface thickened to accommodate weight bearing
- Inferior surface contains the acetabular (cotyloid) notch, which is bound by the transverse acetabular ligament.

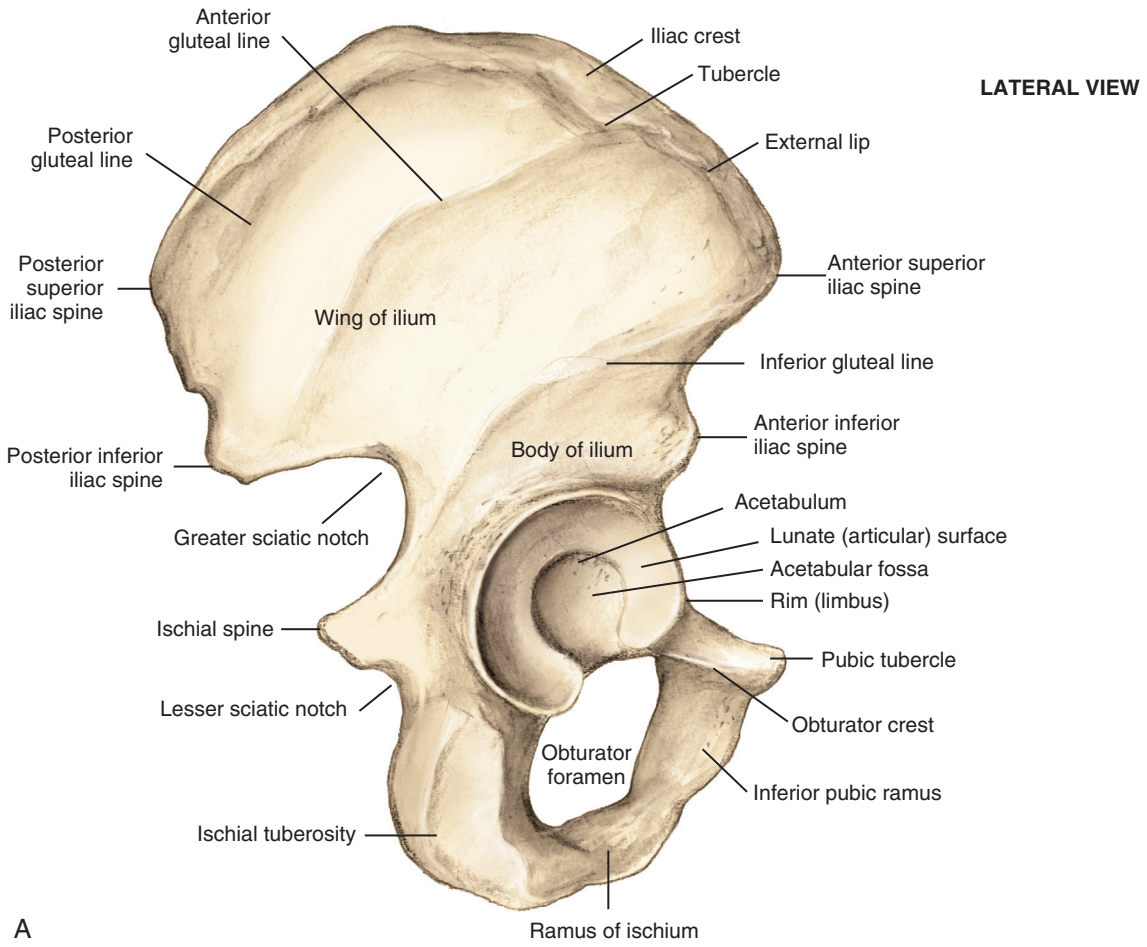
■ Femur

- Proximal femur: femoral head, femoral neck, and greater and lesser trochanters
 - Femoral head blood supply changes with age (Table 2-27).
 - **Pediatric femoral nail insertion: piriformis starting point threatens the posterosuperior retinacular vessels (potential for femoral head avascular necrosis [AVN]).**
 - **Adult posterior hip approach: do not completely transect the quadratus femoris muscle (to prevent damage to medial femoral circumflex artery).**
 - Femoral neck normally anteverted approximately 14 degrees in relation to femoral condyles (range 1-40 degrees)
 - Femoral neck shaft angle averages 127 degrees (begins at 141 degrees in the fetus).
 - Proximal femoral trabecular architecture is illustrated in Figure 2-46.
- Femoral shaft: anterior bow
- Ossification: important areas of femoral ossification include the head and the distal femur.
 - Femoral head is usually not present at birth but appears as one large physis that includes both trochanters at about the age of 11 months and fuses at age 18 years.
 - **Slipped capital femoral epiphysis occurs through the femoral head physis (zone of hypertrophy).**
 - Distal femoral epiphysis is present at birth and fuses at age 19 years.

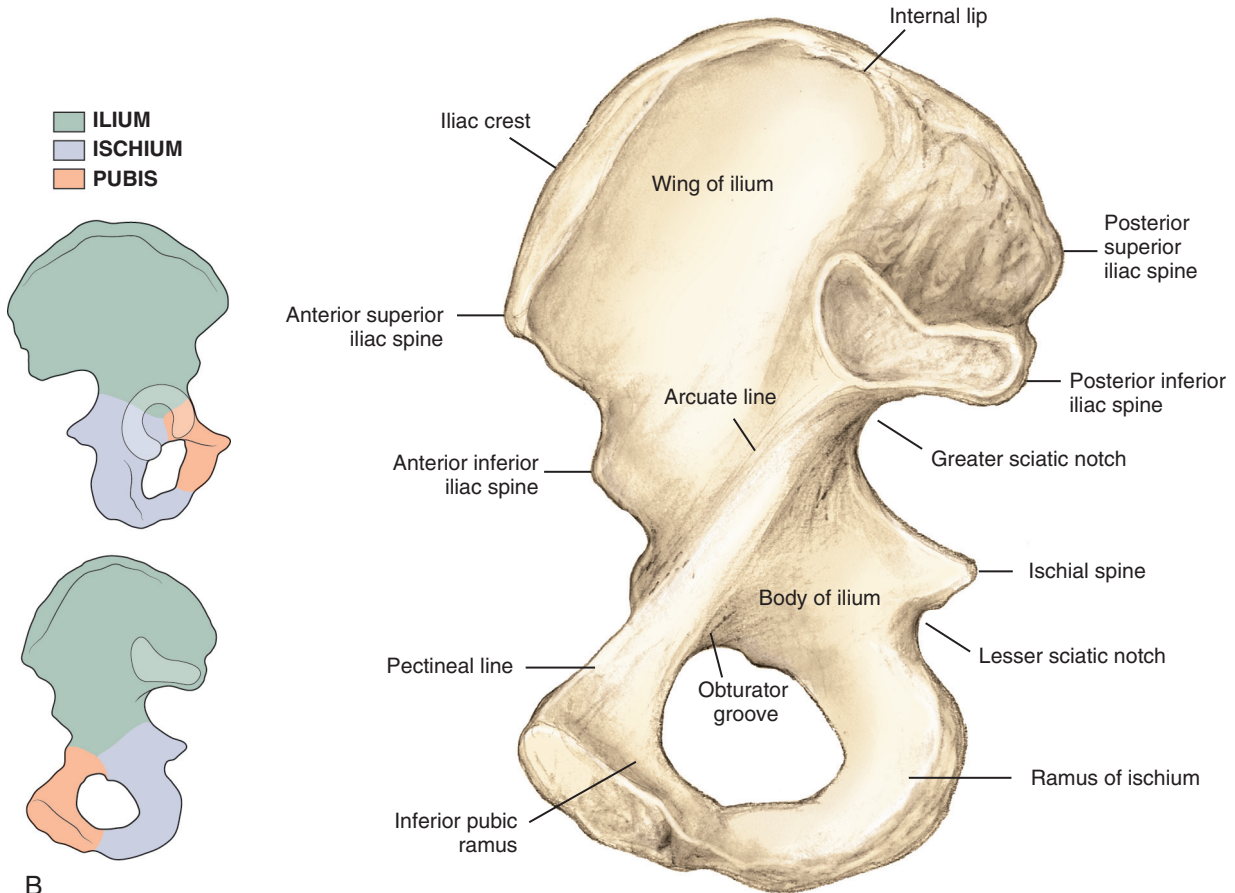
■ Arthrology

■ Hip (Figure 2-47)

- Ball-and-socket diarthrodial joint
- Stability is based primarily on the bony architecture.
- **Fibrocartilaginous labrum deepens acetabulum, enhancing stability. Labral functions include load transmission, maintenance of vacuum seal, regulation of synovial fluid hydrodynamics, and joint lubrication.**



A



B

FIGURE 2-45 **A**, Osseous anatomy of the outer portion of the hemipelvis. **B**, Osseous anatomy of the inner portion of the hemipelvis from the sacroiliac joint to the pubic symphysis. (From Miller MD et al: *Orthopaedic surgical approaches*, ed 2, Philadelphia, 2014, Saunders, Figures 6-1 and 6-2.)

Table 2-27 Age-Dependent Changes to Blood Supply to Femoral Head

AGE	BLOOD SUPPLY
Birth to 4 yr	Primary medial and lateral circumflex arteries (from deep femoral artery) Ligamentum teres with posterior division of obturator artery
4 yr to adult	Negligible amount from lateral circumflex artery Minimal amount from ligamentum teres Posterosuperior and posteroinferior retinacular from medial femoral circumflex artery
Adult	Medial femoral circumflex to lateral epiphyseal artery

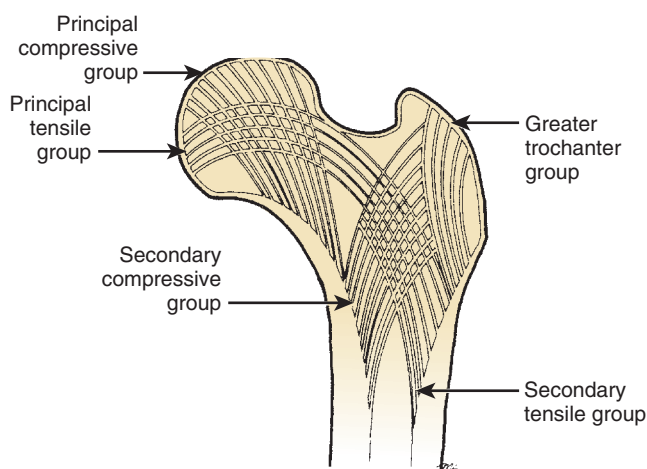


FIGURE 2-46 Hip trabeculae. Trabecular patterns help determine the presence of osteopenia and displacement of femoral neck fractures. (From DeLee JC: *Fractures and dislocations of the hip*. In Rockwood CA Jr et al, editors: *Fractures in adults*, ed 3, Philadelphia, 1991, JB Lippincott, p 1488.)

- Hip joint capsule: extends anteriorly to intertrochanteric crest but posteriorly only partially across femoral neck
 - **Basicervical and intertrochanteric crest regions are extracapsular.**
 - Capsular ligaments
 - **Iliofemoral ligament (Y ligament of Bigelow) is the strongest ligament in the body and attaches AIIS to intertrochanteric line in an inverted Y manner.**
 - Ischiofemoral and pubofemoral ligaments are weaker but provide additional stability.
 - Capsule tight in extension, relaxed in flexion
 - Ligamentum teres: arises from apex of cotyloid notch and attaches to fovea of femoral head
 - Transmits an arterial branch of the posterior division of the obturator artery to femoral head (less significant in adults)
- Sacroiliac joint
 - Stabilized by posterior and anterior sacroiliac ligaments and interosseous ligaments
- Symphysis pubis
 - Stabilized by superior and arcuate pubic ligaments and contains fibrocartilaginous disc

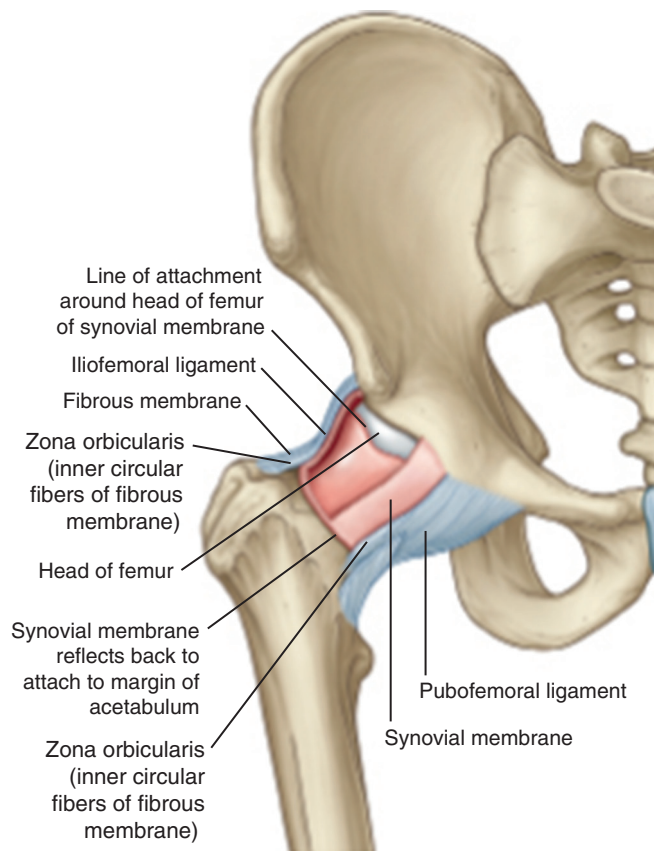


FIGURE 2-47 Ligaments and membranes of the hip joint. (From Drake RL et al, editors: *Gray's atlas of anatomy*, ed 2, Philadelphia, 2015, Churchill Livingstone.)

■ **Muscles that act on the hip joint (Figures 2-48 and 2-49; Table 2-28)**

- Hip flexion: iliopsoas, rectus femoris, and sartorius
- Hip extension: gluteus maximus and hamstrings (semitendinosus, semimembranosus, and long head of biceps femoris)
- Hip abduction: gluteus medius and minimus (primary); tensor fasciae latae (TFL) helps with abduction in a flexed hip.
- Hip adduction: adductors brevis, longus, and magnus, pectineus, and gracilis
- Hip external rotation: obturator internus, obturator externus, superior and inferior gemellus, quadratus femoris, and piriformis
- Hip internal rotation: secondary actions of anterior fibers of gluteus medius and gluteus minimus, TFL, semimembranosus, semitendinosus, pectineus, and posterior part of adductor magnus

■ **Muscles of the thigh that do not cross the hip joint are listed in Table 2-29.**

■ **Muscles with dual innervation**

- Pectineus (obturator and femoral)
- Adductor magnus (obturator and tibial)
- **Biceps femoris (long head, tibial nerve; short head, peroneal nerve)**
- **Muscles that cross the hip and knee (more prone to strain injury)**
 - Rectus femoris (hip flexion, knee extension)
 - Sartorius (hip flexion, knee flexion)



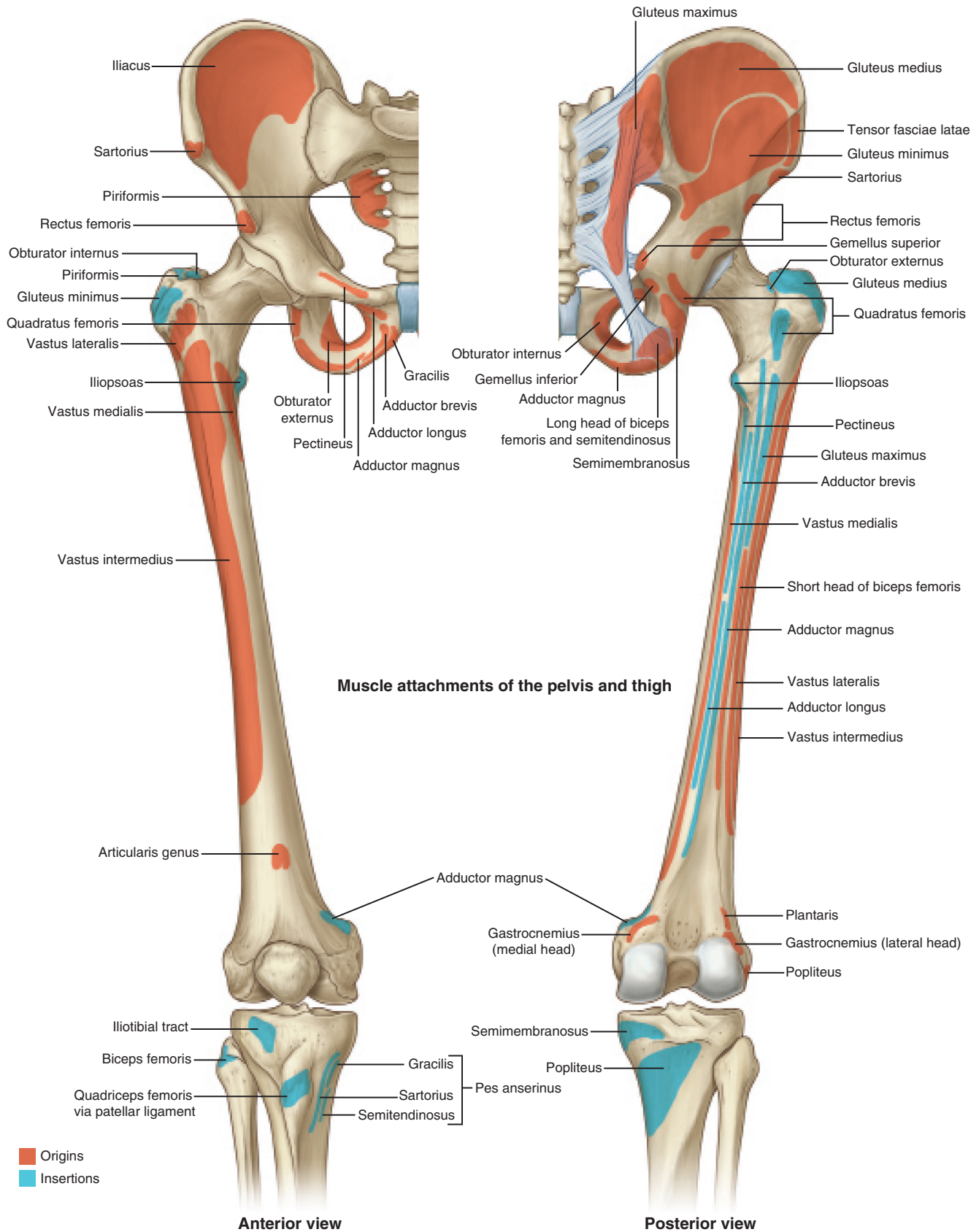


FIGURE 2-48 Muscle attachments of the pelvis and thigh. (From Drake RL et al, editors: *Gray's atlas of anatomy*, ed 2, Philadelphia, 2015, Churchill Livingstone.)

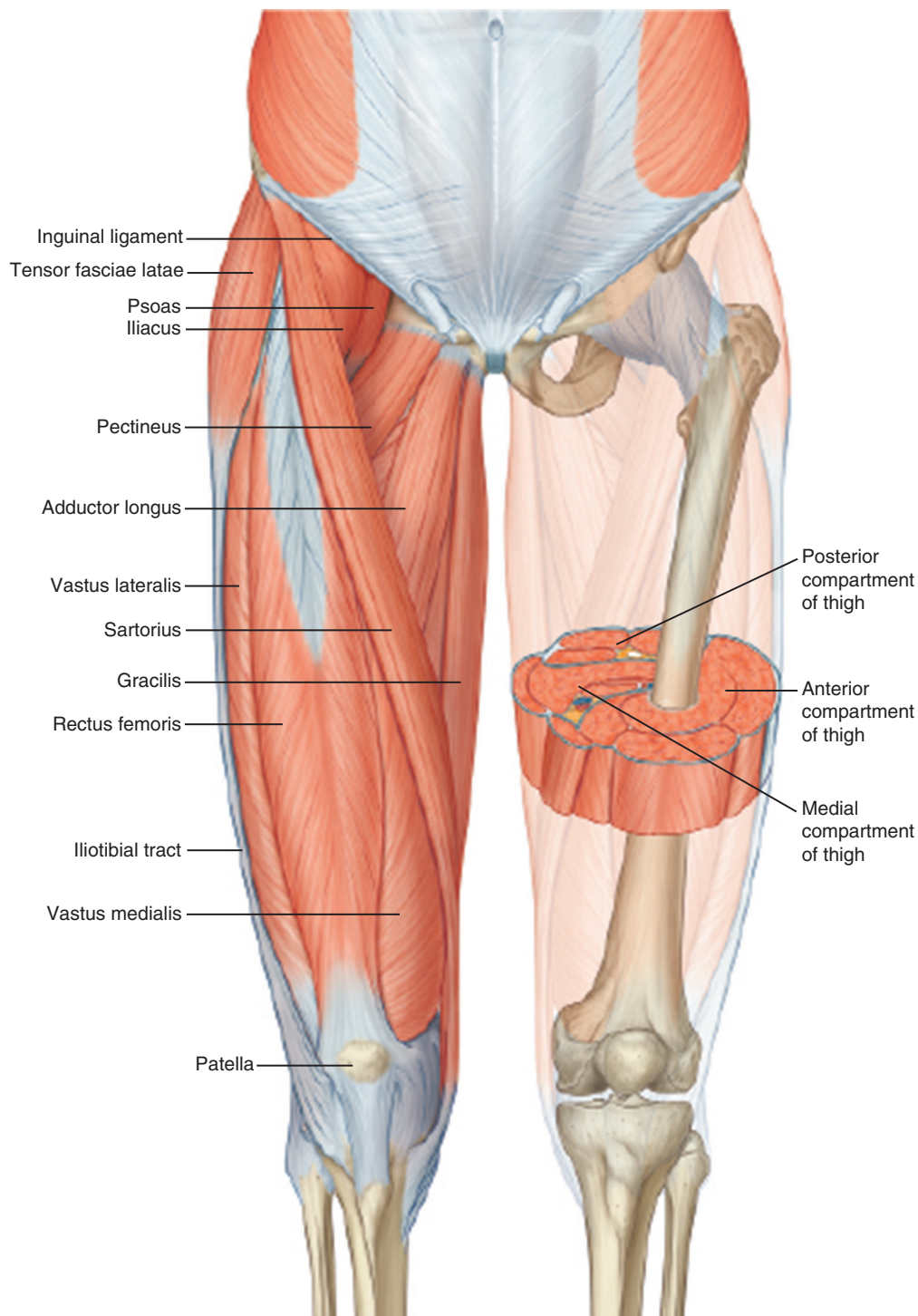


FIGURE 2-49 Thigh muscles and compartments. (From Drake RL et al, editors: *Gray's atlas of anatomy*, ed 2, Philadelphia, 2015, Churchill Livingstone.)

- Gracilis (hip adduction, knee flexion)
- Biceps femoris, long head (hip extension, knee flexion)
- Semimembranosus (hip extension, knee flexion)
- Semitendinosus (hip extension, knee flexion)

KNEE AND LEG

■ Osteology

- Distal femur
 - Two femoral condyles (**medial condyle is larger**)
 - More prominent medial epicondyle supports the adductor tubercle.
- Sulcus terminalis on lateral femoral condyle
- Tibia
 - **Proximal medial facet (oval and concave) and lateral facet (circular and convex)**
 - Gerdy tubercle on lateral side of the proximal tibia is the insertion of the iliotibial (IT) tract.
 - Tibial shaft is triangular in cross section and tapers to its thinnest point at the junction of the middle and distal thirds before widening again to form the tibial plafond.
- Fibula
 - Fibular head attachment point for lateral collateral ligament and insertion point for biceps femoris

Table 2-28 Muscles That Act on the Hip

MUSCLE	ORIGIN	INSERTION	NERVE	SEGMENT
FLEXORS				
Iliacus	Iliac fossa	Lesser trochanter	Femoral	L2-L4 (P)
Psoas	Transverse processes of L1-L5	Lesser trochanter	Femoral	L2-L4 (P)
Pectineus	Pectineal line of pubis	Pectineal line of femur	Femoral and obturator	L2-L4 (P)
Rectus femoris	Anterior inferior iliac spine, acetabular rim	Patella and tibial tubercle	Femoral	L2-L4 (P)
Sartorius	Anterior superior iliac spine	Proximal medial tibia	Femoral	L2-L4 (P)
EXTENSORS				
Biceps femoris (long head)	Medial ischial tuberosity	Fibular head/lateral tibia	Tibial	L5-S2 (A)
Semitendinosus	Distal medial ischial tuberosity	Anterior tibial crest	Tibial	L5-S2 (A)
Semimembranosus	Proximal lateral ischial tuberosity	Oblique popliteal ligament Posterior capsule Posterior/medial tibia Popliteus Medial meniscus	Tibial	L4-S3 (A)
ADDUCTORS				
Adductor magnus	Inferior pubic ramus/ischial tuberosity	Linea aspera/adductor tubercle	Obturator (P) and tibial	L2-L4 (A)
Adductor brevis	Inferior pubic ramus	Linea aspera/pectineal line	Obturator (P)	L2-L4 (A)
Adductor longus	Anterior pubic ramus	Linea aspera	Obturator (A)	L2-L4 (A)
Gracilis	Inferior symphysis/pubis arch	Proximal medial tibia	Obturator (A)	L2-L4 (A)
EXTERNAL ROTATORS				
Gluteus maximus	Ilium, posterior gluteal line	Iliotibial band/gluteal sling (femur)	Inferior gluteal	L5-S2 (P)
Piriformis	Anterior sacrum/sciatic notch	Proximal greater trochanter	Piriformis	S2 (P)
Obturator externus	Ischiopubic rami/obturator	Trochanteric fossa	Obturator	L2-L4 (A)
Obturator internus	Ischiopubic rami/obturator membrane	Medial greater trochanter	Obturator internus	L5-S2 (A)
Superior gemellus	Outer ischial spine	Medial greater trochanter	Obturator internus	L5-S2 (A)
Inferior gemellus	Ischial tuberosity	Medial greater trochanter	Quadratus femoris	L5-S1 (A)
Quadratus femoris	Ischial tuberosity	Quadratus line of femur	Quadratus femoris	L5-S1 (A)
ABDUCTORS				
Gluteus medius	Ilium between posterior and anterior gluteal lines	Greater trochanter	Superior gluteal	L4-S1 (P)
Gluteus minimus	Ilium between anterior and inferior gluteal lines	Anterior border of greater trochanter	Superior gluteal	L4-S1 (P)
Tensor fasciae latae (tensor fasciae femoris)	Anterior iliac crest	Iliotibial band	Superior gluteal	L4-S1 (P)

A, Anterior; P, posterior.

Table 2-29 Muscles of the Thigh

MUSCLE	ORIGIN	INSERTION	INNERVATION
ANTERIOR THIGH			
Vastus lateralis	Iliotibial line/greater trochanter/lateral linea aspera	Lateral patella	Femoral
Vastus medialis	Iliotibial line/medial linea aspera/supracondylar line	Medial patella	Femoral
Vastus intermedius	Proximal anterior femoral shaft	Patella	Femoral
POSTERIOR THIGH			
Biceps femoris (long head)	Medial ischial tuberosity	Fibular head/lateral tibia	Tibia
Biceps (short head)	Lateral linea aspera/lateral intermuscular septum	Lateral tibial condyle	Peroneal
Semitendinosus	Distal medial ischial tuberosity	Anterior tibial crest	Tibial
Semimembranosus	Proximal lateral ischial tuberosity	Oblique popliteal ligament Posterior capsule Posterior/medial tibia Popliteus Medial meniscus	Tibial

tendon; popliteofibular ligament attaches to fibular styloid process.

- Fibular neck has a groove for the common peroneal nerve.
- Patella: the largest sesamoid bone
 - Serves three functions:
 - Fulcrum for quadriceps to facilitate knee extension
 - Protects knee joint
 - Enhances lubrication and nutrition of knee
 - Accessory or “bipartite” patella may represent failure of fusion of the superolateral corner of the

patella and is commonly confused with patellar fractures.

■ Arthrology

■ Knee (Figure 2-50)

- Enclosed in a capsule that has posteromedial and posterolateral recesses extending 15 mm distal to the subchondral surface of the tibial plateau (be careful to avoid intraarticular pin placement).
- Medial and lateral femoral condyles articulate with corresponding tibial facets. Shape of tibial plateau confers greater articular congruity medially than

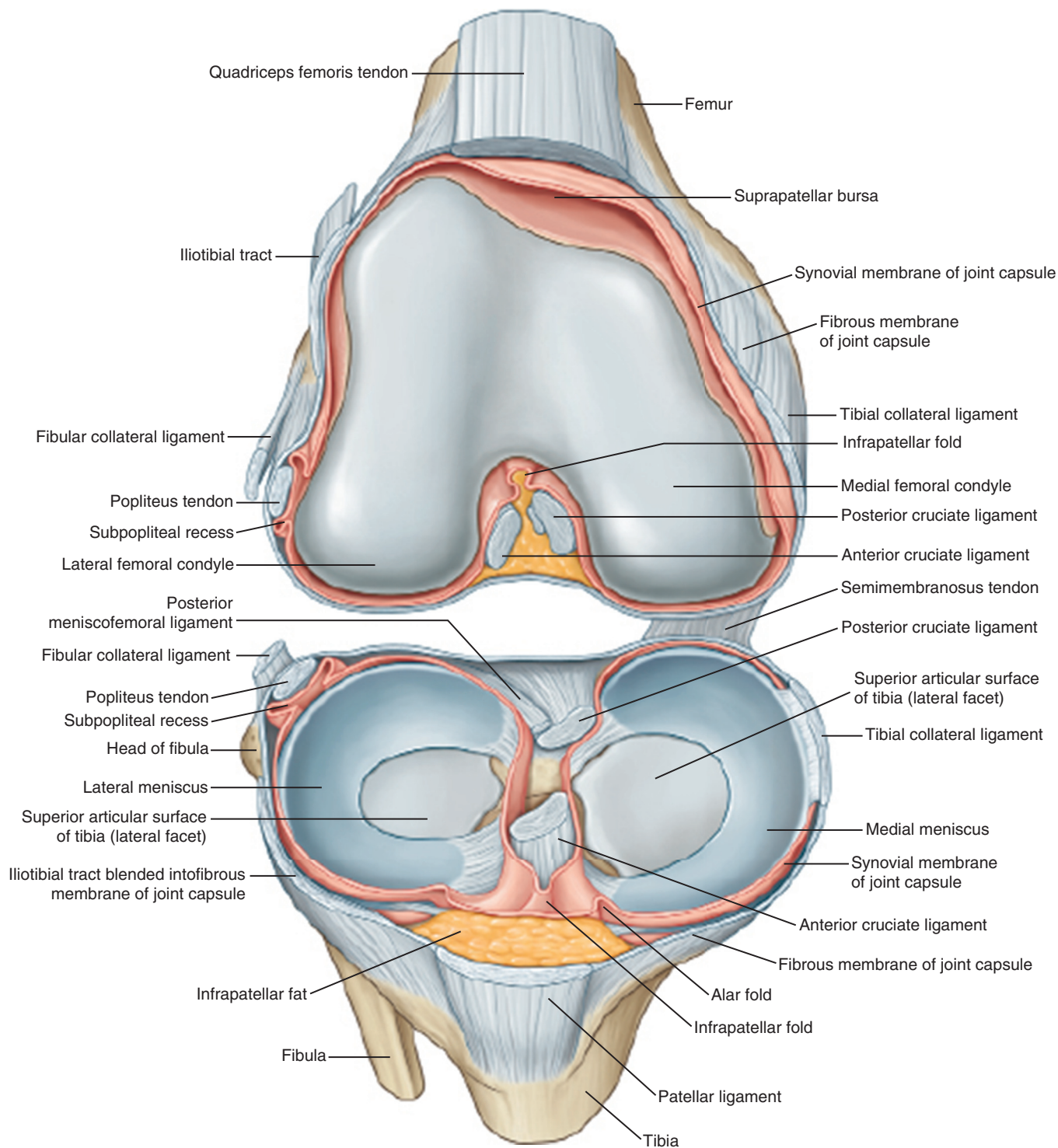


FIGURE 2-50 Anatomy of the Knee. (From Drake RL et al, editors: *Gray's atlas of anatomy*, ed 2, Philadelphia, 2015, Churchill Livingstone.)

laterally (important when considering consequences of meniscectomy).

- Menisci
 - Serve to deepen concavity of facets, help protect the articular surface, and assist in rotation of the knee
 - **Peripheral third of menisci are vascular and can be repaired (red zone); inner two thirds are nourished by synovial fluid (white zone) and have limited healing capacity.**
- Medial meniscus tears three times more often than the more mobile lateral meniscus.
 - **Must protect saphenous nerve during medial meniscus repair**
- Lateral meniscus is associated with meniscal cysts and discoid menisci; most common site of tears in acute injuries to the anterior cruciate ligament (ACL).
 - Protect peroneal nerve during lateral meniscus repair.

Table 2-30 Ligaments of the Knee

LIGAMENT	PROXIMAL ATTACHMENT	DISTAL ATTACHMENT	FUNCTION
ANTERIOR KNEE			
Retinacular	Vastus medialis and vastus lateralis, tibial condyles	Medial and lateral patella	Forms anterior capsule
Medial patellofemoral	Between adductor tubercle and medial femoral epicondyle (Schottle point)	Superomedial patella	Resists lateral translation of patella
POSTERIOR KNEE			
Posterior fibers	Femoral condyles	Tibial condyles	Forms posterior capsule
Oblique popliteal	Semimembranosus tendon	Lateral femoral condyle/posterior capsule	Strengthens capsule
MEDIAL KNEE			
Superficial MCL	Medial femoral epicondyle	Medial tibial metaphysis	Resists valgus force
Deep MCL	Medial femoral epicondyle/medial meniscus	Medial tibial condyle/medial meniscus	Resists valgus force, stabilizes medial meniscus
Posterior oblique	Adductor tubercle	Posteromedial tibia	Resists valgus force, internal rotation
LATERAL KNEE			
Lateral collateral	Lateral epicondyle	Lateral fibular head	Resists varus force
Popliteofibular ligament	Popliteus tendon	Fibular styloid process	Resists external rotation
Arcuate ligament	Lateral femoral condyle, over popliteus	Posterior tibia/fibular head	Posterior support
CRUCIATES/INTRAARTICULAR LIGAMENTS			
Anterior cruciate	Posteromedial lateral femoral condyle	Anterior intercondylar tibia	Resists anterior translation, hyperextension
Posterior cruciate	Anteromedial femoral condyle	Posterior sulcus of tibia	Resists posterior translation, hyperflexion
Humphrey	Medial femoral condyle (anterior to PCL)	Posterolateral meniscus	Stabilizes lateral meniscus
Wrisberg	Medial femoral condyle (posterior to PCL)	Posterolateral meniscus	Stabilizes lateral meniscus
Transverse meniscal	Anteromedial meniscus	Anterolateral meniscus	Stabilizes menisci

MCL, Medial collateral ligament; PCL, posterior collateral ligament.

• Ligaments

- Stability of the knee is enhanced by a complex arrangement of ligaments (Table 2-30).
- Cruciate ligaments are crucial for anteroposterior stability; collateral ligaments provide varus and valgus stability.
- Each cruciate ligament is made up of two portions, or bundles. Anterior bundles of each cruciate tight in flexion.
- **ACL has anteromedial (tight in flexion) and posterolateral (tight in extension) bundles; PL bundle tested with pivot shift exam.**
 - Mnemonic: “AMPLE” (AnteroMedial and PosteroLateral bundle, PL tight in Extension)
- PCL has anterolateral (tight in flexion) and posteromedial (tight in extension) bundles.
 - Mnemonic: “PAL” (PCL has anterolateral bundle)
- Ligament of Humphrey (anterior to PCL) and the Wrisberg ligament (posterior to PCL). Mnemonic: *H* comes before *W* in alphabet; Humphrey is anterior, Wrisberg posterior.
- MCL has superficial and deep component; superficial MCL attaches 5 to 7 cm distal to joint (Figure 2-51)
- Posterior oblique ligament resists internal rotation with knee in full extension.
- **Posterolateral corner (PLC): fibular collateral ligament, popliteus tendon, and popliteofibular ligament; other PLC structures include biceps femoris tendon, lateral head of gastrocnemius, biceps femoris, arcuate ligament, and posterolateral capsule (Figure 2-52, A and B).**

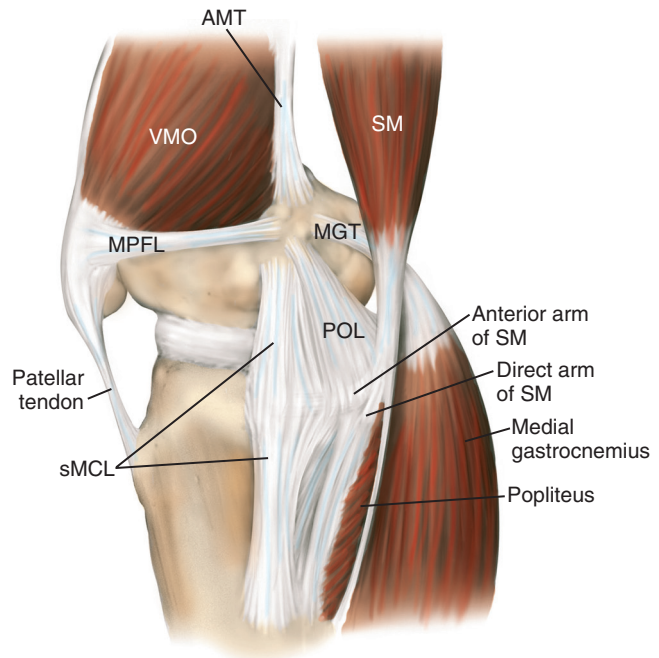


FIGURE 2-51 Illustration of the main medial knee structures (right knee). (From Scott WN: *Insall & Scott surgery of the knee*, ed 5, Philadelphia, 2012, Elsevier, Figure 39-3.)

- Isolated injuries to the PCL cause the greatest instability at 90 degrees of knee flexion.
- Combined injuries of the PCL and PLC result in increasing instability as the knee is flexed from 30 to 90 degrees.

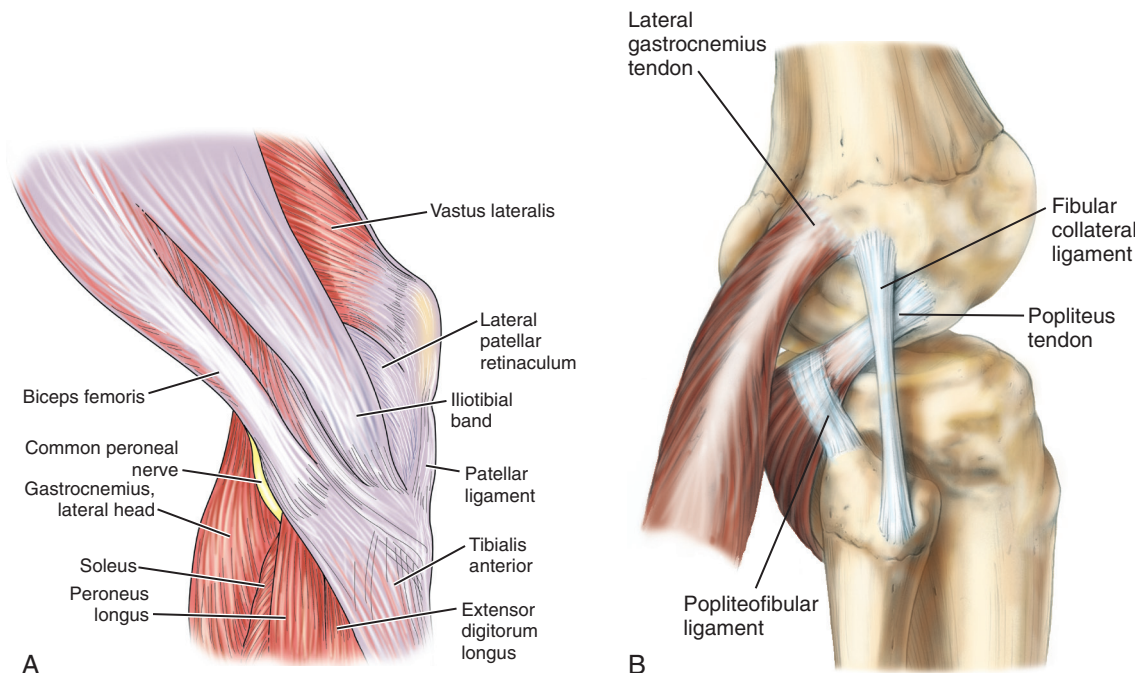


FIGURE 2-52 A, Lateral aspect of the knee, layer 1. B, Drawing of lateral knee dissection. (From Scott WN: *Insall & Scott surgery of the knee*, ed 5, Philadelphia, 2012, Elsevier, Figures 1-70 and 40-1.)

- Dial test: rotational instability at 30 degrees = PLC injury, at 30 and 90 degrees = combined PLC + PLC injury
- MPFL runs from proximal third of medial patella to Schottle's point on the femur (between adductor tubercle and medial epicondyle); just distal to vastus medialis obliquus
- Proximal tibiofibular joint: strengthened by the anterior and posterior ligaments of the head of the fibula
- **Muscles and tendons around the knee**
- Several muscles and tendons traverse the knee, giving it dynamic stability.
- Popliteal fossa is bordered by the gastrocnemius lateral and medial heads, the semimembranosus, and the biceps; the plantaris muscle makes up the floor of the fossa.
- Autograft hamstrings for ACL reconstruction: gracilis and semitendinosus (run deep to the sartorial fascia and superficial to the superficial MCL); saphenous nerve at risk with harvest
- **Muscles of the leg**
- Origins and insertions are noted in [Figure 2-53](#).
- Divided into compartments (anterior, lateral, superficial posterior, and deep posterior) ([Figure 2-54](#), [Table 2-31](#))
 - Anterior and lateral compartments are supplied by the common peroneal nerve (anterior supplied by the deep peroneal nerve, and lateral supplied by the superficial peroneal nerve) and contain postaxial muscles.
 - Posterior compartments are supplied by the tibial nerve and contain preaxial muscles.
 - **Four compartment releases of the leg are key testable material** and are summarized in [Table 2-32](#). The saphenous nerve (termination of the femoral nerve) is subcutaneous.

ANKLE AND FOOT

■ Osteology

■ Ankle

- Distal tibia flares to form an inferior quadrilateral surface for articulation with the talus and the pyramid-shaped medial malleolus.
- Laterally, the fibular notch forms articulation with the fibula.
- Lateral malleolus: distal fibula expansion that extends beyond distal tip of medial malleolus and serves as lateral buttress of ankle joint

■ Foot

- 26 bones of the foot: 7 tarsal bones, 5 metatarsals, and 14 phalanges
- Divided into the hindfoot (talus and calcaneus), midfoot (navicular, cuboid, and three cuneiforms), and forefoot (metatarsals and phalanges)
- Tarsals: includes talus, calcaneus, cuboid, navicular, and three cuneiforms
- Talus ([Figure 2-55](#))
 - Trochlea (including surfaces for the malleoli articulations)
 - Posterior and middle calcaneal facets (body)
 - Anterior calcaneal facet (head)
 - Two thirds of the talus is covered with cartilage; no muscular attachments.
 - **Groove posteriorly for the tendon of the FHL. Os trigonum (if present) lateral to FHL.**
 - Posterior process (for posterior talofibular ligament)
 - Talar body wider anteriorly, conferring greater stability with ankle in dorsiflexion
 - Talar neck connects with the head, which in turn articulates with the navicular distally and the calcaneus inferiorly.
 - **Primary blood supply to the talar body is from the artery of the tarsal canal (posterior tibial artery) ([Figure 2-56](#)).**

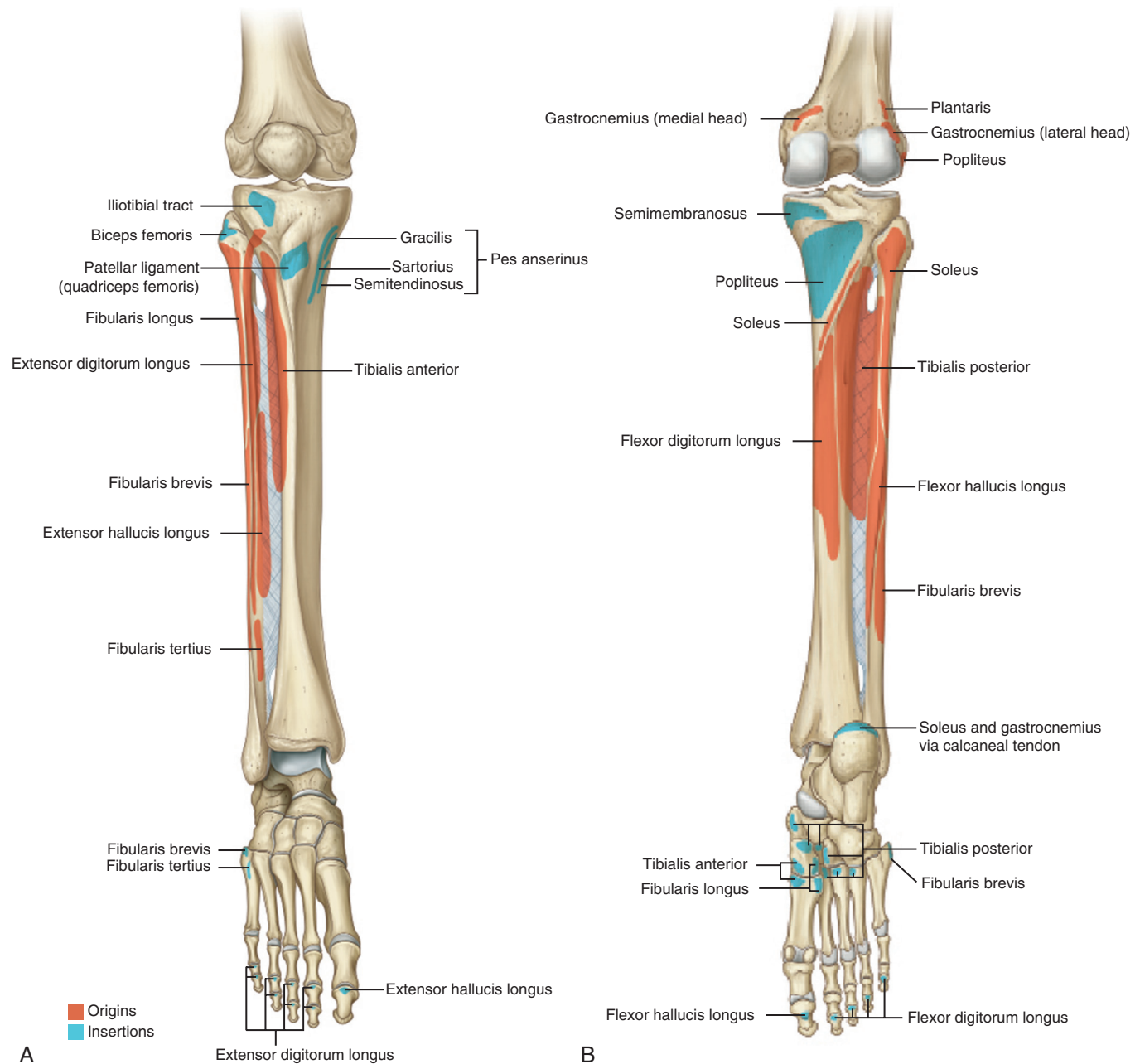


FIGURE 2-53 Origins and insertions of muscles of the leg. (From Drake RL et al, editors: *Gray's atlas of anatomy*, ed 2, Philadelphia, 2015, Churchill Livingstone.)

- Other blood supply is from the superior neck vessels (anterior tibial artery) and the artery of the tarsal sinus (dorsalis pedis).
- Calcaneus
 - Three surfaces that articulate with the talus: a large posterior facet, an anterior facet, and a middle facet
 - Distally, an articular surface receives the cuboid bone.
 - Sustentaculum tali is an overhanging horizontal eminence on the anteromedial surface of the calcaneus.
 - Supports the middle articular surface above it and has an inferior groove for the FHL tendon
- Cuboid
 - Grooved on the plantar surface by the peroneus longus
- Four facets for articulation with the calcaneus, the lateral cuneiform, and the fourth and fifth metatarsals
- Navicular
 - Most medial tarsal bone, the navicular lies between the talus and the cuneiforms.
 - Proximally, the surface is oval and concave for its articulation with the head of the talus.
 - Distally, the navicular has three articular surfaces, one for each of the cuneiforms.
 - Medial plantar projection serves as the insertion for the posterior tibial tendon.
- Cuneiforms (Figure 2-57)
 - Three bones (medial, intermediate, and lateral)
 - Articulate with the navicular and posterior cuboid (lateral cuneiform) and the first three metatarsals

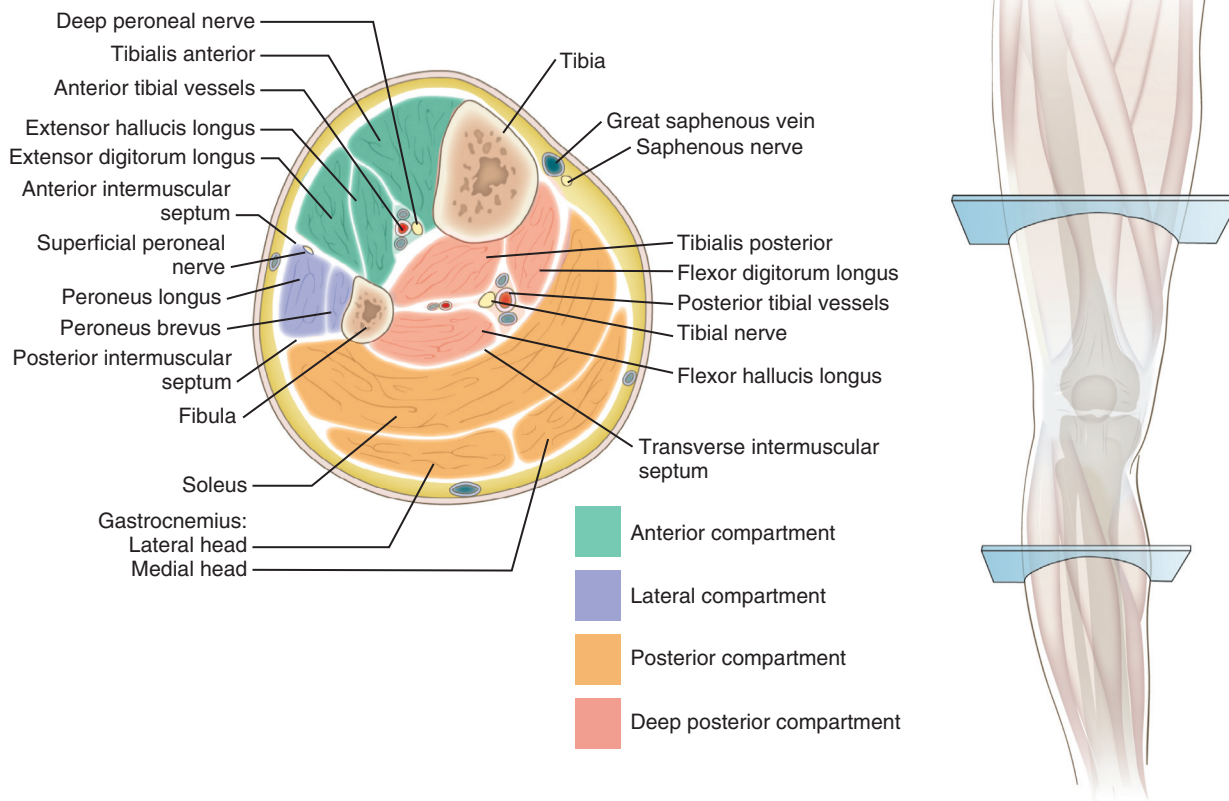


FIGURE 2-54 Anterior and lateral compartment release. (From DeLee JC, Drez D Jr: *Orthopaedic sports medicine: principles and practice*, Philadelphia, 1994, WB Saunders, p 1618.)

Table 2-31 Muscles of the Leg		MUSCLE	ORIGIN	INSERTION	ACTION	INNERVATION
ANTERIOR COMPARTMENT						
	Tibialis anterior	Lateral tibia	Medial cuneiform, first metatarsal	Dorsiflexing, inverting foot	Deep peroneal (L4) nerve	
	Extensor hallucis longus	Midfibula	Great toe, distal phalanx	Dorsiflexing, extending toe	Deep peroneal (L5) nerve	
	Extensor digitorum longus	Tibial condyle/fibula	Toe, middle and distal phalanges	Dorsiflexing, extending toe	Deep peroneal (L5) nerve	
	Peroneus tertius	Fibula and extensor digitorum longus tendon	Fifth metatarsal	Everting, dorsiflexing, abducting foot	Deep peroneal (S1) nerve	
LATERAL COMPARTMENT						
	Peroneus longus	Proximal fibula	Medial cuneiform, first metatarsal	Everting, plantar flexing, abducting foot	Superficial peroneal (S1) nerve	
	Peroneus brevis	Distal fibula	Tuberosity of fifth metatarsal	Everting foot	Superficial peroneal (S1) nerve	
SUPERFICIAL POSTERIOR COMPARTMENT						
	Gastrocnemius	Posterior medial and lateral femoral condyles	Calcaneus	Plantar flexing foot	Tibial (S1) nerve	
	Soleus	Fibula/tibia	Calcaneus	Plantar flexing foot	Tibial (S1) nerve	
	Plantaris	Lateral femoral condyle	Calcaneus	Plantar flexing foot	Tibial (S1) nerve	
DEEP POSTERIOR COMPARTMENT						
	Popliteus	Lateral femoral condyle, fibular head	Proximal tibia	Flexing, internally rotating knee	Tibial (L5, S1) nerve	
	Flexor hallucis longus	Fibula	Great toe, distal phalanx	Plantar flexing great toe	Tibial (S1) nerve	
	Flexor digitorum longus	Tibia	Second to fifth toes, distal phalanges	Plantar flexing toes, foot	Tibial (S1, S2) nerve	
	Tibialis posterior	Tibia, fibula, interosseous membrane	Navicular, medial cuneiform	Inverting/plantar flexing foot	Tibial (L4, L5) nerve	

- Intermediate cuneiform does not extend as far distally as the medial cuneiform, which allows the second metatarsal to “key” into place.
- Metatarsals
 - Five bones, numbered from a medial to lateral direction, span the distance between the tarsal bones and phalanges.
 - Shape and function are similar to those of the metacarpals of the hand.
 - First metatarsal has a plantar crista that articulates with the **fibular and tibial sesamoids contained within the flexor hallucis brevis tendon.**

- Phalanges
 - Similar to those of the hand. Great toe (analogous to thumb) has two phalanges, and the remaining digits have three.
- Ossification
 - Each tarsal bone has a single ossification center except for the calcaneus, which has a second center posteriorly.
 - Calcaneus, talus, and usually the cuboid are present at birth.
 - Lateral cuneiform appears during the first year, the medial cuneiform during the second year, and the intermediate cuneiform and navicular during the third year.
 - Posterior center for the calcaneus usually appears during the eighth year.
 - The second through fifth metatarsals have two ossification centers:
 - Primary center in the shaft
 - Secondary center for the head, which appears at ages 5 to 8 years
 - Phalanges and first metatarsal have secondary centers at their bases that appear proximally during the third or fourth year and distally during the sixth or seventh year.

Table 2-32 Compartment Releases of Leg

COMPARTMENT	MUSCLES	NEUROVASCULAR STRUCTURES RELEASED
Anterior	Tibialis anterior, extensor hallucis longus, extensor digitorum longus, peroneus tertius	Deep peroneal nerve and anterior tibial artery
Lateral	Peroneus longus and brevis	Superficial peroneal nerve
Superficial posterior	Gastrocnemius-soleus complex, plantaris	Sural nerve
Deep posterior	Popliteus, flexor hallucis longus, flexor digitorum longus, tibialis posterior	Posterior tibial artery and vein, tibial nerve, peroneal artery and vein

Arthrology

- Distal tibiofibular joint
 - Formed by the medial distal fibula and the notched lateral distal tibia
- Ankle syndesmosis (connection between the tibia and fibula) supported by four ligaments: anterior and posterior inferior tibiofibular ligaments, a

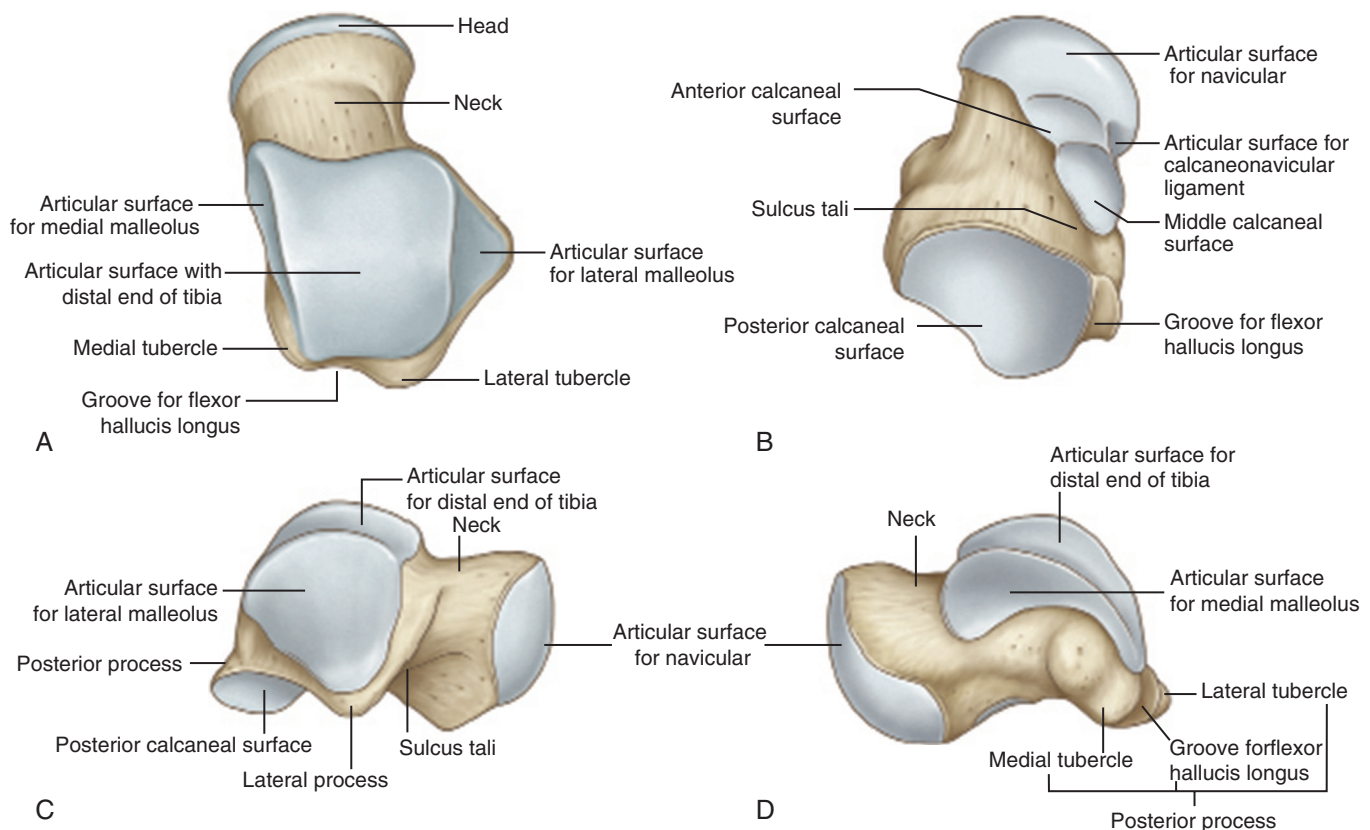


FIGURE 2-55 Talus from different angles. (From Drake RL et al, editors: *Gray's atlas of anatomy*, ed 2, Philadelphia, 2015, Churchill Livingstone.)

transverse tibiofibular ligament, and an interosseous ligament. Syndesmotic injury often referred to as “high-ankle sprain.”

- Anteroinferior tibiofibular ligament (AITFL) is an oblique band that connects the bones anteriorly. Bony avulsion of this ligament in adolescents may result in a Tillaux fracture.
- Ankle joint (Table 2-33)
 - Mortise formed by the medial and lateral malleoli, tibial plafond, and talus
 - Deltoid ligament composed of two layers (Figure 2-58)
 - Superficial layer (tibionavicular and tibiocalcaneal) crosses ankle and subtalar joint.
 - Deep layer (anterior and posterior tibiotalar) crosses ankle joint only.
 - Lateral fibular ligaments: anterior talofibular ligament (ATFL), calcaneofibular ligament (CFL), and posterior talofibular ligament (PTFL) (Figure 2-59)
 - ATFL is the weakest and is intracapsular (intracapsular thickening). Injured with lateral ankle sprain.
 - CFL crosses subtalar joint.
 - **Position of the ankle is critical when the lateral ligament complex is tested. Plantar flexion tightens the anterior talofibular ligament, and**

inversion with neutral flexion tightens the calcaneofibular ligament.

- Subtalar joint
 - Talar plantar facets articulate with the calcaneus (Figure 2-60).
 - Stability is derived from four ligaments: medial ligament, lateral ligament, interosseous talocalcaneal ligament, and cervical ligament.
 - Intertarsal joints: several ligamentous structures are important (Table 2-34).
 - **Plantar calcaneonavicular ligament (spring ligament) supports head of talus; attenuated in pes planus deformity (Figure 2-61).**
- Other joints
 - Tarsometatarsal joints are gliding joints supported by dorsal, plantar, and interosseous ligaments.
 - Base of first metatarsal is not ligamentously connected to second metatarsal.
 - **Lisfranc ligament connects medial (shortest) cuneiform to second (longest) metatarsal.**
 - Plantar and dorsal structure in about 20% of patients
 - Deep transverse metatarsal ligaments interconnect metatarsal heads.
 - Digital nerve courses in a plantar direction under the transverse metatarsal ligament and is the spot where

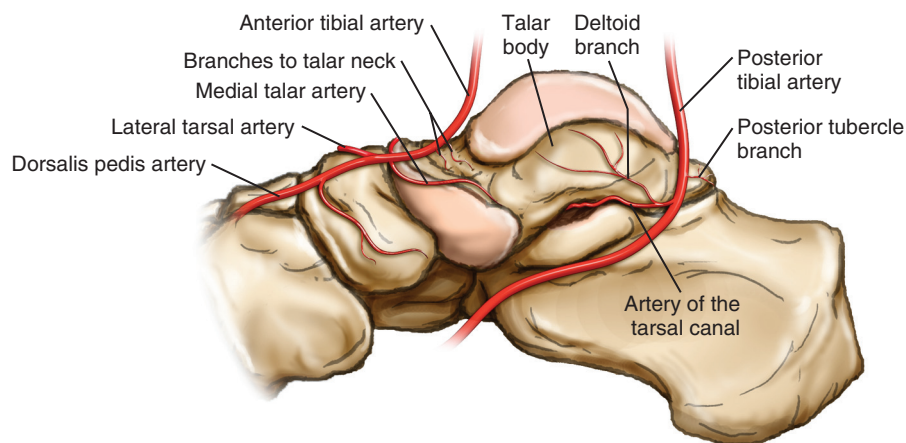


FIGURE 2-56 Arterial supply to the talus. (From Miller MD et al: *Orthopaedic surgical approaches*, Philadelphia, 2008, Saunders, Figure FA-26.)

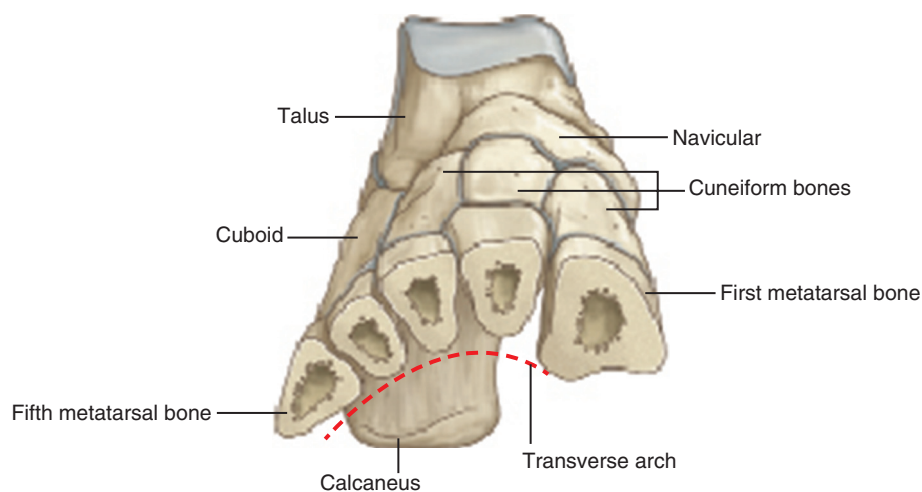
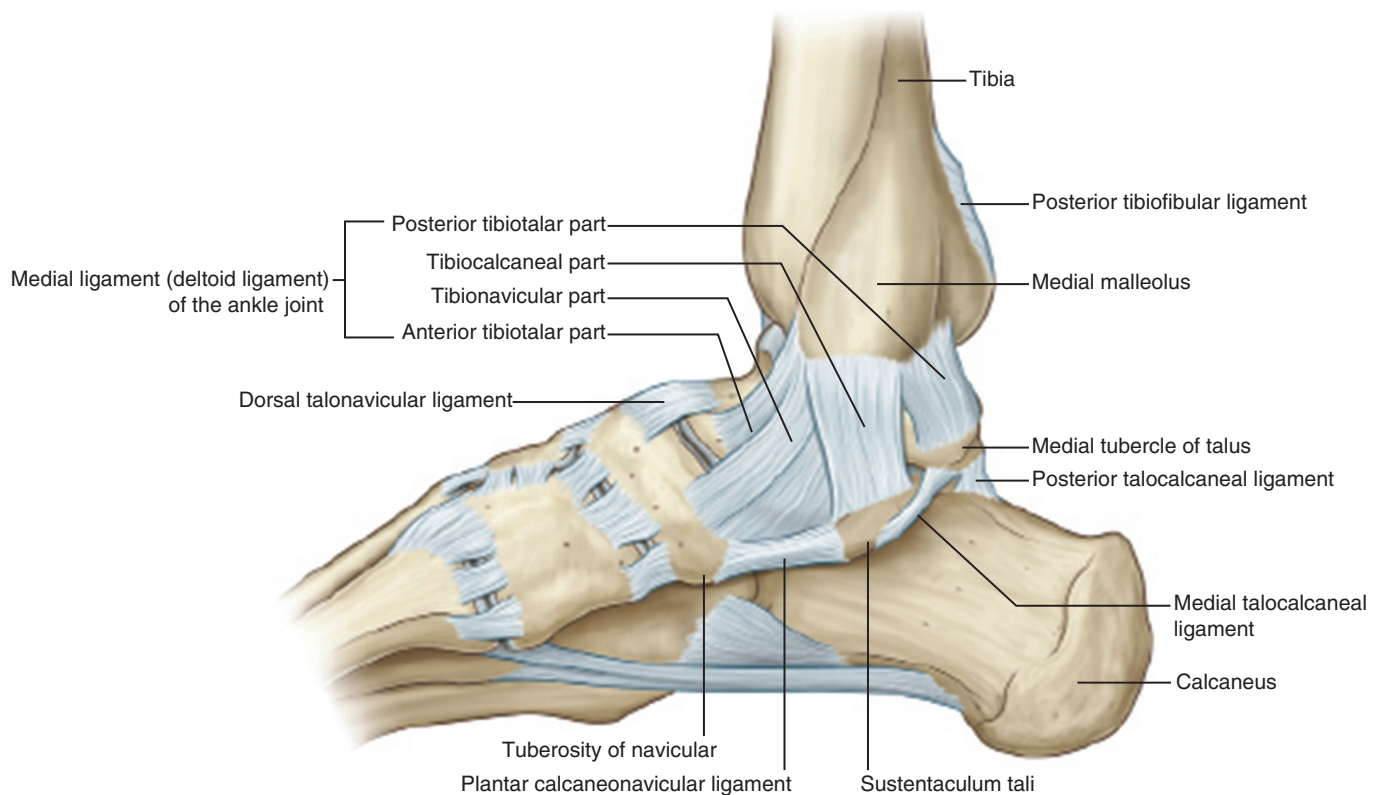


FIGURE 2-57 Bones of the foot. (From Drake RL et al, editors: *Gray's atlas of anatomy*, ed 2, Philadelphia, 2015, Churchill Livingstone.)

Table 2-33 Ankle Joint Ligaments

LIGAMENT	PROXIMAL ATTACHMENT	DISTAL ATTACHMENT	FUNCTION
TIBIOFIBULAR (SYNDESMOSIS)			
Anterior inferior tibiofibular	Tibia	Fibula	Stability of ankle mortise
Interosseous ligament	Tibia	Fibula	Stability of ankle mortise
Posterior inferior tibiofibular ligament	Tibia	Fibula	Stability of ankle mortise
MEDIAL ANKLE (DELTOID)			
Tibionavicular	Medial malleolus	Navicular tuberosity	Limits talar external rotation
Tibiocalcaneal	Medial malleolus	Sustentaculum tali	Limits hindfoot eversion
Anterior tibiotalar	Medial malleolus	Medial surface of talus	Limits lateral displacement of talus, external rotation
Posterior tibiotalar	Medial malleolus	Inner side of talus	Limits lateral displacement
LATERAL ANKLE			
Anterior talofibular	Lateral malleolus	Transversely to talus anteriorly	Limits inversion in plantar flexion
Calcaneofibular	Lateral malleolus	Obliquely to calcaneus posteriorly	Limits inversion in neutral or dorsiflexion
Posterior talofibular	Lateral malleolus	Transversely to talus posteriorly	Limits posterior talar displacement and external rotation

**FIGURE 2-58** Ligaments of the foot. (From Drake RL et al, editors: *Gray's atlas of anatomy*, ed 2, Philadelphia, 2015, Churchill Livingstone.)

interdigital neuritis (Morton neuroma, usually the second or third interdigital space) occurs.

- Transverse metatarsal ligament attaches second metatarsal head to fibular sesamoid.
- Holds hallucal sesamoids in place and gives the appearance of sesamoid subluxation when the first metatarsal moves medially in hallux valgus.
- Plantar and collateral ligaments support the metatarsophalangeal joints.
 - Primary stabilizing structure of the metatarsophalangeal joint is the plantar plate.
- Interphalangeal joints are supported mainly by their capsules.

■ Muscles

- Origins and insertions of muscles are shown in [Figure 2-62](#).
- Major tendons ([Figure 2-63](#)) crossing the ankle joint include:
 - Anterior (from lateral to medial): peroneus tertius, extensor digitorum longus (EDL), extensor hallucis longus (EHL), tibialis anterior
 - **Medial (mnemonic: “Tom, Dick, and Harry”): tibialis posterior, flexor digitorum longus, and flexor hallucis longus**
 - Lateral: peroneal tendons with longus (superficial) and brevis (deep)

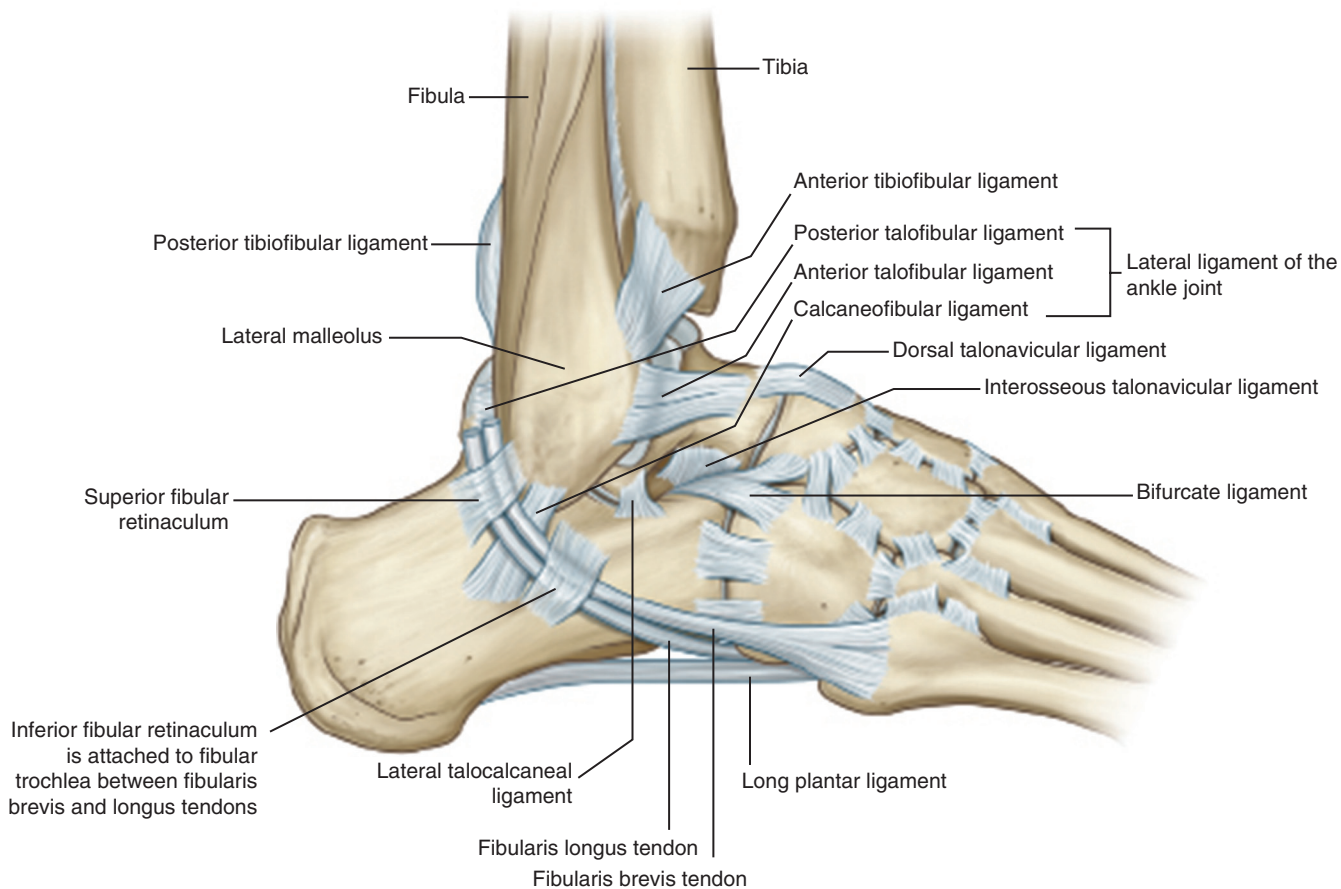


FIGURE 2-59 Ligaments of the foot. (From Drake RL et al, editors: *Gray's atlas of anatomy*, ed 2, Philadelphia, 2015, Churchill Livingstone.)

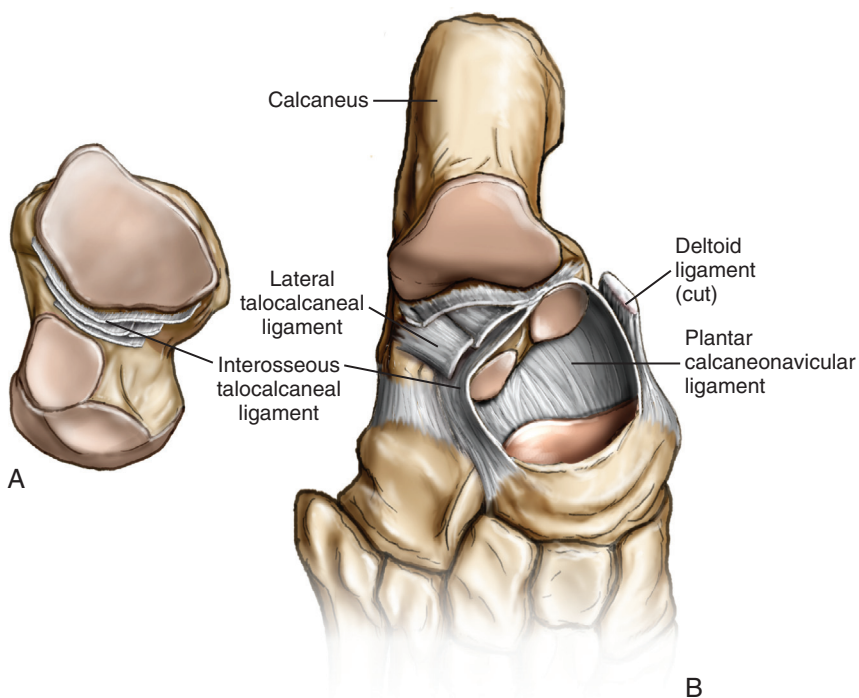


FIGURE 2-60 **A**, Inferior view of the talus showing the interosseous ligament. **B**, Dorsal view of the hindfoot (after removal of the talus) showing the calcaneal facets with the spring ligaments. (From Miller MD et al: *Orthopaedic surgical approaches*, ed 2, Philadelphia, 2014, Saunders, Figure 8-7.)